

Meeting the patient challenges of sore peristomal skin; through patient assessment, discussion and the appropriate use of accessories


Contact: info@securicaremedical.co.uk

Jill Coulthard, RGN, Stoma Care Nurse, SecuriCare (Medical) Ltd.

Denise Carter, RGN, Stoma Care Nurse, SecuriCare (Medical) Ltd.

Lynn Ridley, RGN, Stoma Care Nurse Manager, SecuriCare (Medical) Ltd.

Moira Evans, RGN, New Product Development Specialist, CliniMed Ltd. moira.evans@clinimed.co.uk



This poster reflects three patient experiences which demonstrate the benefits of appropriately prescribed accessories and the impact that these can have on their quality of life. The nursing management of these patients relates to the patient identified needs of adherence, security and overall comfort to improve the quality of life for patients with complex stomas alleviating problematic peristomal skin.


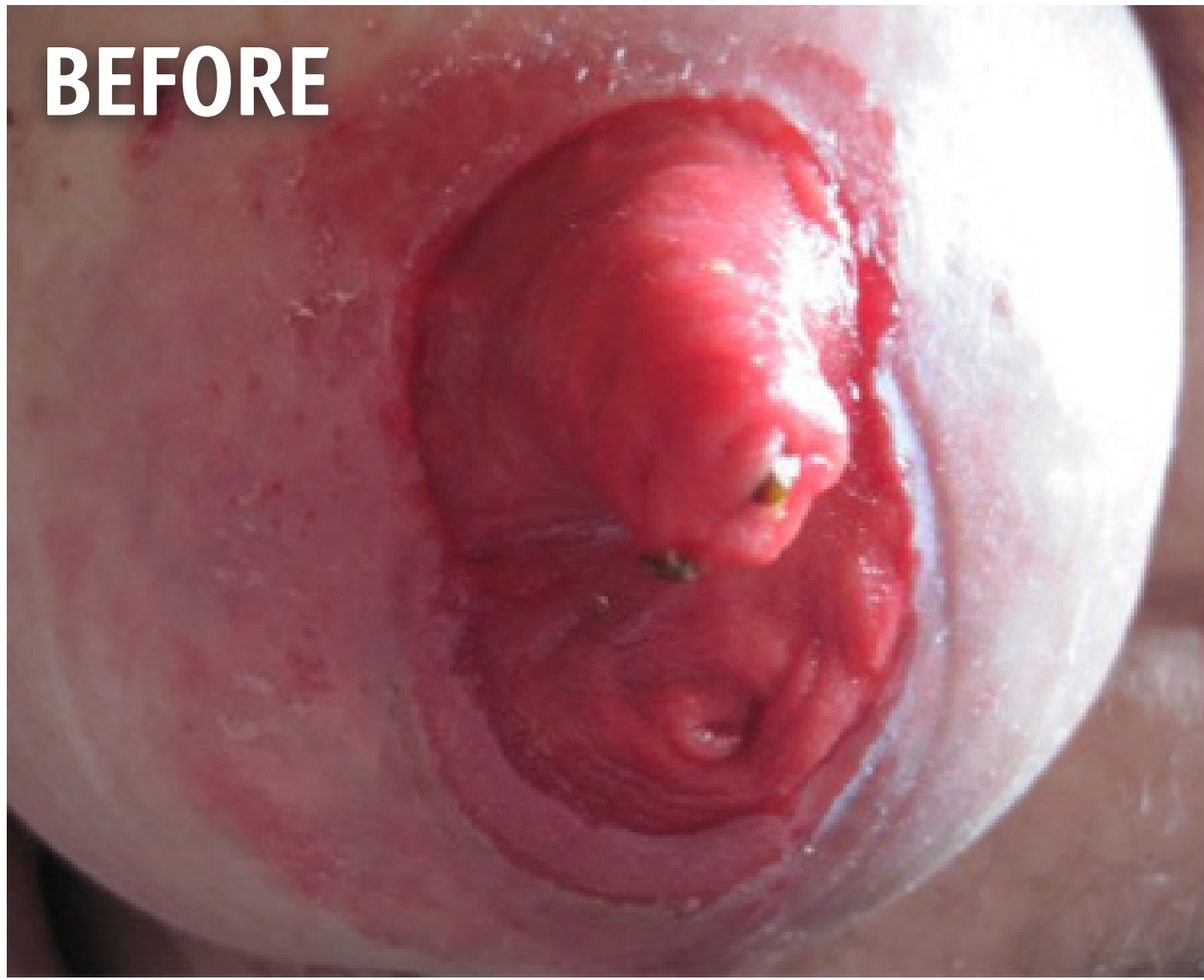
ADHERENCE Case Study One

Mrs A, 67 year old with a loop ileostomy and the development of a post-operative parastomal hernia.

BEFORE: Mrs A was introduced to flange extenders to manage the lack of adherence for the flange due to the abnormal shaping around the stoma site caused by the parastomal hernia. Her skin had improved significantly following the change to an Aura pouch. The new HydroFrame with Manuka honey flange extender gave her the opportunity to improve the peristomal skin integrity with the same hydrocolloid with Manuka honey.

AFTER: Following seven days of evaluation it was evident that the benefit of the HydroFrame with Manuka honey flange extender had improved the skin integrity whilst enabling the pouch to remain secure and no leaks were detected. Reviewing the peristomal skin condition, it is evident that her skin was less red and the irritation was almost alleviated.

OUTCOME: Mrs A no longer experiences any leakages with her pouch following the use of HydroFrame with Manuka honey, Mrs A commented that she found it was “easier to mould, more flexible to apply and made her skin better”. She no longer needs to apply a barrier to the peristomal skin.





SKIN INTEGRITY Case Study Two

Mr B, a 42 year old who had a history of ulcerative colitis and underwent a total colectomy and formation of end ileostomy in 2013. In January 2014 a parastomal hernia was diagnosed.

BEFORE: The poor adherence of the pouch had resulted in regular leaks which caused peristomal skin irritation causing discomfort and affecting his quality of life. The picture below highlights the impact of the skin irritation and also the prominence of the parastomal hernia.

AFTER: The decision to introduce HydroFrame with Manuka honey flange extender was taken to alleviate the skin irritation whilst providing a larger base for the stoma flange to adhere to with the aim of increasing the pouch wear time. The picture highlights the change in the peristomal skin condition during the evaluation period.

OUTCOME: Mr A found that his skin was less irritated, he felt more comfortable whilst the pouch was in situ and that the pouch and flange extender provided a more flexible base for the pouch, overall he felt more comfortable.



SECURITY Case Study Three

Mrs C, a 75 year old who underwent a panproctocolectomy 41 years ago due to an acute onset of ulcerative colitis.

BEFORE: Mrs C’s stoma sits within a moat which contributes to the peristomal skin becoming sore in areas and itchy. During this time she was experiencing leakage which affected her achievement of a desired 2 days wear time from her pouch. Despite trying a combination of products, which helped reduce the issue of leakage, her skin remained excoriated in certain areas and had impacted upon the healing process.

AFTER: Mrs C found that she was able to increase the wear time of her pouch to two days following the use of the HydroFrame with Manuka honey flange extender and Hyperseal with Manuka Honey washer for seven days.

OUTCOME: Mrs C had achieved her 2 day wear time target. Her confidence levels had increased as she felt that the products were more mouldable, easier to apply and that she been able to ensure a stronger seal for the pouch to adhere to. She reported that her skin felt less itchy and overall more comfortable.



SUMMARY: Three nurses demonstrated three positive outcomes for three patients demonstrating that appropriate use of stoma accessories can make a difference in the management of complex stoma challenges. The improvement of adherence led to increased security and comfort which enhanced the quality of life for the three patients involved. Rudoni and Dennis (2009) discussed the need for specialist stoma services to deliver patient reviews. The evaluation outcomes demonstrates the appropriate use of stoma accessories, as shown by the case studies the products met the individual needs of the patients.

Reference Rudoni, C., Dennis, H. (2009) Accessories or necessities? Exploring consensus on usage of stoma accessories. British Journal of Nursing Vol 18, No 19 p 1106-11

Photographs used within this poster are with the consent of the patients involved and preserve anonymity.

PID1026